

# Clinicopathological Correlation of Non Oncological Hysterectomies at a Tertiary Healthcare Centre

KALPANA SHARMA



## ABSTRACT

**Introduction:** Hysterectomy is a common surgical procedure for benign gynaecologic pathologies despite the availability of conservative treatment options. However, studies indicate many health and psychosexual complications following this procedure. Regular histopathological audit of hysterectomies in relation to the clinical rationale will provide valuable data and insight and thus, lead to improved knowledge and expertise.

**Aim:** To correlate clinical and histopathological diagnosis in hysterectomies for non oncological indications and assess the agreement between the two modalities.

**Materials and Methods:** A retrospective cross-sectional study with comparative clinicopathological analysis which included 702 hysterectomies for non oncological indications during a one-year period (April 2019 to March 2020) was carried out in the Department of Pathology at a tertiary healthcare centre in Ajmer, Rajasthan, India. Cohen-kappa value was determined to measure the degree of agreement between clinical and histopathological diagnosis. A comparative clinicopathological analysis was done by segregating cases into two categories-those with structural pathologies and the other with non structural/functional pathologies.

**Results:** A total of 702 hysterectomy specimens were studied. The clinicopathological concordance for structural lesions was better than functional aetiologies (87.52% vs 57.8%). Leiomyoma was the most frequent clinical and histopathological diagnosis. Histopathology revealed more structural lesions than clinically suspected (81.2% vs 75.36%). The Cohen-kappa value revealed an overall fair agreement between clinical and histopathological judgement ( $\kappa=0.27$ ). Clinicopathological-agreement was lower in adenomyosis, dual structural pathologies while it was better for polyps, leiomyomas, obstetric pathologies and procidentia.

**Conclusion:** Although, an overall fair degree of agreement was found between clinical and histopathological diagnosis, conditions that lack a specific clinical presentation or a sensitive diagnostic test like adenomyosis showed poor clinicopathological agreement. Histopathology is a vital tool to verify the appropriateness of the clinical indication of hysterectomies. Frequent clinicopathological correlation helps in improving knowledge and expertise of the healthcare provider, thus improving future clinical judgements.

**Keywords:** Adenomyosis, Benign gynaecologic pathologies, Histopathological audit, Leiomyoma, Polyps

## INTRODUCTION

Hysterectomy is a commonly performed surgical procedure for benign pathologies like leiomyoma, Abnormal Uterine Bleeding (AUB), chronic pelvic pain, adenomyosis, pelvic inflammatory disease (PID), endometriosis despite the availability of several effective medical and conservative treatment options. Although the incidence of hysterectomy in India is lower than western nations, owing to its longterm side effects, it has emerged as an important issue in debates on healthcare and medical ethics [1].

There is growing evidence to indicate that many health and psychosexual complications occur following hysterectomy [2-7]. Postmenopausal symptoms start prematurely in at least 30% of women within two years post hysterectomy despite preservation of adnexa [8]. This implies that uterus should not be considered as just an organ for child bearing and its functions have an overall impact on the quality of a woman's life. Thus, the decision for hysterectomy should be meticulously planned after thorough discussion and counselling of the patients.

Histopathology helps to confirm the suspected clinical indication for hysterectomy and allows to verify the appropriateness of the surgical procedure.

Regular histopathological audit of hysterectomy specimens for non oncological indications gives an overall perspective to the clinician regarding the structural pathologies that were histologically confirmed, as well as additional or alternate structural pathologies that were hitherto clinically missed. This improves the knowledge and expertise of the healthcare provider, helping them make better

future clinical decisions thus, augmenting the quality of healthcare provided to the patient.

The present study was undertaken to correlate clinical and histopathological diagnosis in hysterectomies that were performed for non oncological indications and to assess the agreement between the two.

## MATERIALS AND METHODS

This was a retrospective cross-sectional study carried out over a period of one year (April 2019 to March 2020) in the Department of Pathology at a tertiary healthcare centre in Ajmer, Rajasthan, India, after taking Institutional Ethical Committee approval (735/Acad-III/MCA/2021;07/04/21). The data analysis was done in the months of April and May 2021.

**Inclusion criteria:** All the hysterectomies performed for non oncological indications during the study period were included.

**Exclusion criteria:** Hysterectomy procedures performed for oncological causes were excluded.

## Study Procedure

Necessary clinical data i.e., age, presenting complaints, clinical indications, type of surgery performed were recorded from the histopathology requisition forms. Identity of the patient and the treating doctor were not recorded. The gross pathological information was retrospectively collected from the histopathology records as all the specimens received for histopathology were routinely subjected to detailed gross examination, noted for the presence of definite structural

abnormalities like leiomyomas, polyps with special attention to endometrial thickness and trabeculations in myometrium for endometrial hyperplasia and adenomyosis respectively. In the presence of polyps and fibroids, their number, location and dimensions were noted. In cases where adnexa (unilateral/bilateral) were received, ovaries and fallopian tube were evaluated separately after taking due measurements. Both external and cut surfaces were thoroughly examined for any obvious structural pathology, foci of endometriosis, cysts. Fallopian tube lumen was examined for any dilatations and collections. Representative tissue samples were taken from cervix (including transformation zone), endometrium, myometrium, adnexa (when present) and any other existing structural lesions like polyps, leiomyomas.

After routine tissue processing, 4-5 micron thick Haematoxylin and Eosin (H&E) stained sections were subjected to detailed microscopic examination. A review of the histological slides was done for arriving at the final histopathological diagnosis.

A comparative clinicopathological analysis was done by segregating cases into two categories-those with structural pathologies and the other with non structural/functional pathologies. The structural group included cases of AUB-PALM (Abnormal Uterine Bleeding-Polyp, Adenomyosis, Leiomyoma, Hyperplasia/Malignancy-as per International Federation of Gynaecology and Obstetrics classification) [9], prolapse, obstetric pathologies, Pelvic Inflammatory Disease (PID) and more than one structural abnormality [dual pathology]. The functional/non structural group were the cases where no definite structural alteration was suspected/seen which included AUB-COIN [Abnormal Uterine Bleeding-Coagulopathy, Ovulatory, Endometrial, Iatrogenic, not otherwise specified- as per International Federation of Gynaecology and Obstetrics classification] [9].

In cases of structural pathologies, it was assessed if histopathology correlated with the primary clinical diagnosis or it showed some additional pathologies or if it showed an entirely different diagnosis altogether. For cases where a functional cause was the indication (AUB-COIN), if the histopathology failed to detect any definite structural pathology it was considered to have justified the primary clinical diagnosis.

## STATISTICAL ANALYSIS

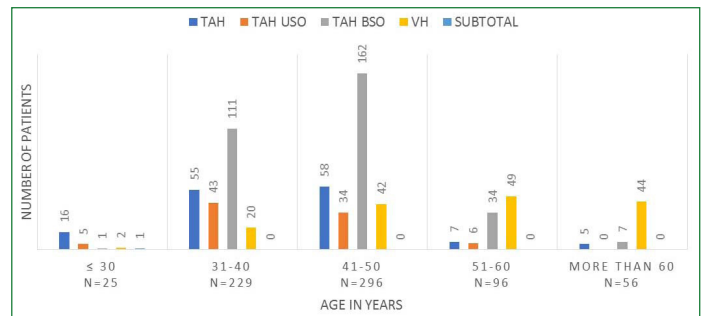
To measure the degree of agreement between clinical and histopathological diagnosis with respect to various structural pathologies, Cohen kappa statistical value ( $\kappa$  value) was determined. For every structural pathology, the following were noted- namely the number of cases in which both the modalities (clinical and histopathological) agreed to include; the number of cases in which both modalities agreed to exclude and the number of cases in which only one of the modalities showed the particular diagnosis.  $\kappa$  value for all the above parameters was determined. Concordance between clinical and histopathological findings was further statistically analysed with p-value less than 0.05 being considered statistically significant. The 3.6.1 version of R software was used in calculating the statistical values.

## RESULTS

During the study period of one year, a total of 702 hysterectomies were performed for non oncological indications. The clinical profile of the patients showed ages ranging from 19-79 years and for the purpose of study were divided into five age group categories with the numbers and type of surgery depicted in detail in [Table/Fig-1]. The various clinical indications for hysterectomy are depicted as a pie-chart in [Table/Fig-2].

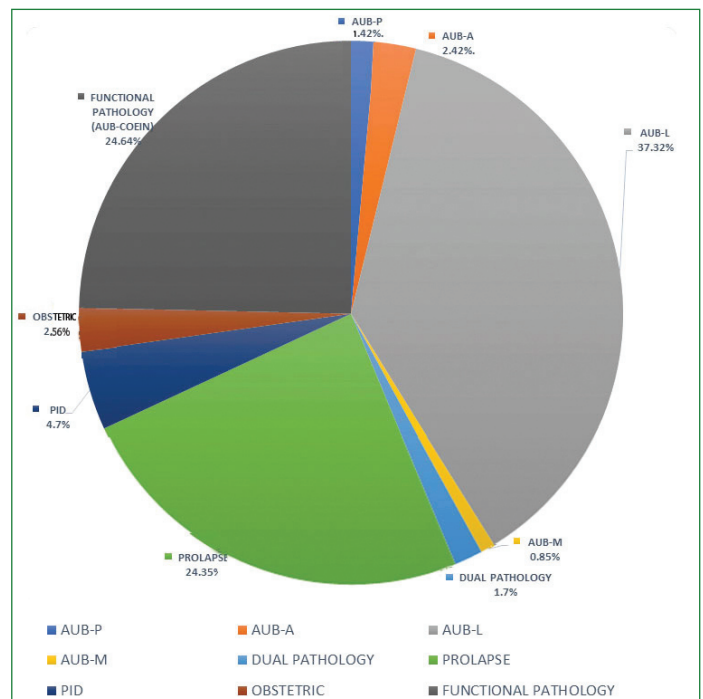
Of the 702 cases a suspected structural pathology (AUB-PALM/ prolapse/PID/ obstetric/dual pathology) was the indication in 529 cases (75.4%) [Table/Fig-3-5] and a functional aetiology (AUB-COIN) in 173 cases (24.6%). AUB-L was overall the most common clinical indication (37.32%;262/702).

Based on the histological findings a final reallocation of the cases was done in the same categories as shown in [Table/Fig-6].



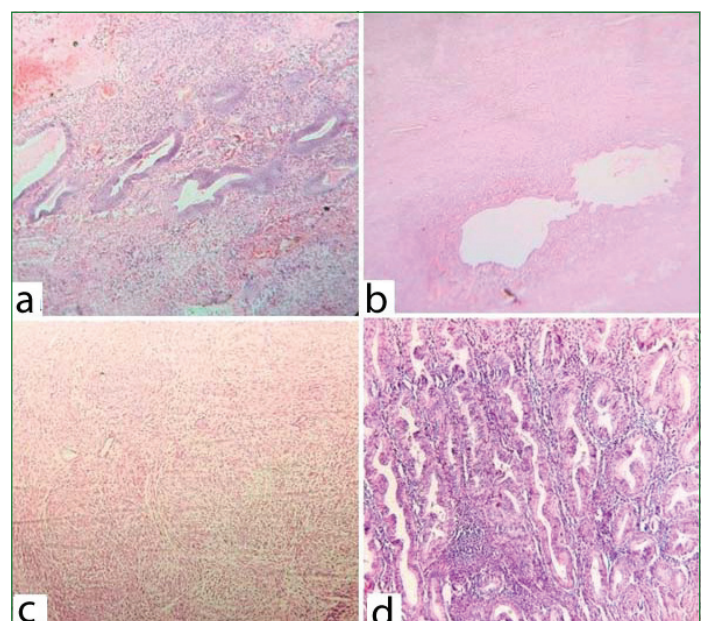
[Table/Fig-1]: Age-wise distribution of Types of hysterectomies.

\*TAH: Total Abdominal Hysterectomy; TAH USO: Total Abdominal Hysterectomy with Unilateral Salpingo-oophorectomy; TAH BSO: Total Abdominal Hysterectomy with Bilateral Salpingo-oophorectomy; VH- Vaginal Hysterectomy; TAH with BSO was the most frequent surgical procedure between age 31-50 years with Abnormal Uterine Bleeding [AUB] being the most common presenting complaint; Vaginal hysterectomy for prolapse dominated in patients older than 51 years. TAH was the most common procedure in the age group less than 30 years as obstetric causes were the predominant indication



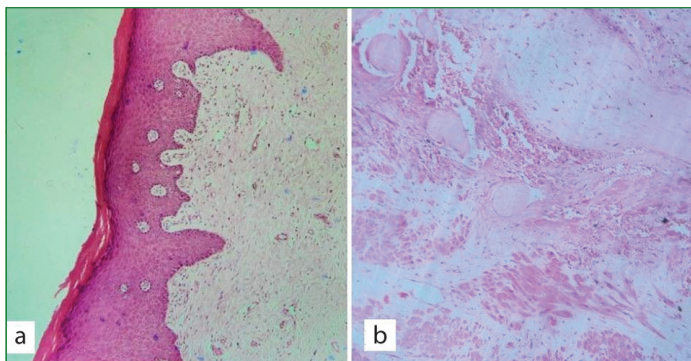
[Table/Fig-2]: Distribution of cases as per primary clinical diagnosis.

\*AUB-P: Abnormal uterine bleeding-polyp; AUB-A: Abnormal uterine bleeding-adenomyosis; AUB-L: Abnormal uterine bleeding-leiomyoma; AUB-M: Abnormal uterine bleeding-hyperplasia/malignancy; PID: Pelvic inflammatory disease; AUB-COIN: Abnormal Uterine Bleeding- Coagulopathy, ovulatory, endometrial, Iatrogenic; Not otherwise specified

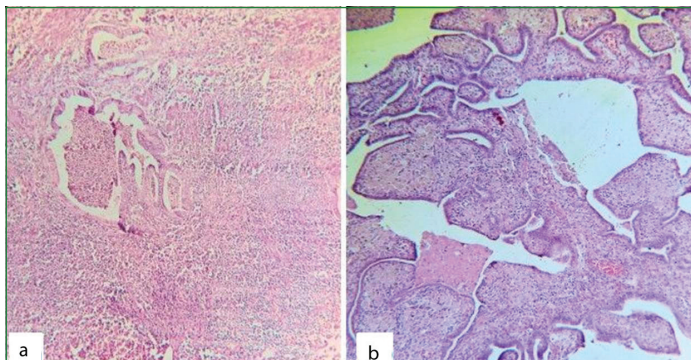


[Table/Fig-3]: Abnormal Uterine Bleeding (AUB)-structural causes PALM Category (Haematoxylin and Eosin stain); a) Endometrial Polyp (P) [x100]; b) Adenomyosis (A) [x40]; c) Leiomyoma (L) [x100]; d) Endometrial hyperplasia without atypia (M) [x100].

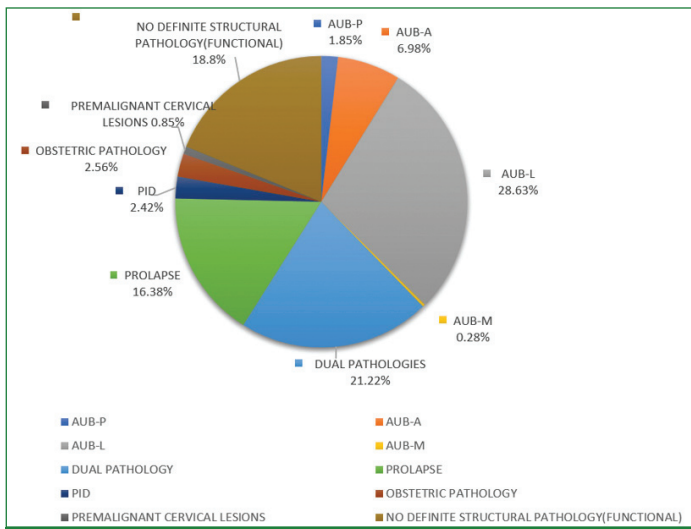




**[Table/Fig-4]:** a) Cervical epithelial changes induced by uterine prolapse [x100]; b) Obstetric causes of hysterectomy- placenta accreta showing chorionic villous implantation directly onto myometrial fibres with no intervening decidua (x100) (Haematoxylin and Eosin stain).



**[Table/Fig-5]:** Pelvic inflammatory disease (Haematoxylin and Eosin stain); a) Chronic Endometritis [x100]; b) Chronic Salpingitis [x100].



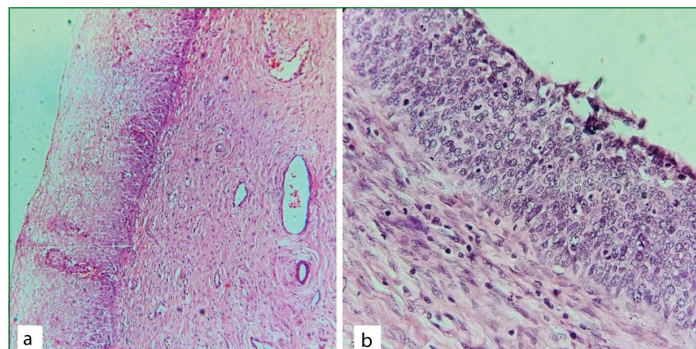
**[Table/Fig-6]:** Distribution of cases as per final histopathological diagnosis. \*AUB-P: Abnormal uterine bleeding-polyp; AUB-A: Abnormal uterine bleeding-adenomyosis; AUB-L: Abnormal uterine bleeding-leiomyoma; AUB-M: Abnormal uterine bleeding-hyperplasia/ malignancy; PID: Pelvic inflammatory disease

Histopathology also showed leiomyoma to be the most common structural pathology (28.63%;201/702) but the overall identification of cases with dual structural pathology showed a marked increase vis-à-vis clinical suspicion (21.2% vs 1.7%). Premalignant cervical lesions, unsuspected clinically were additionally detected in 6/702 cases (0.85%) [Table/Fig-7].

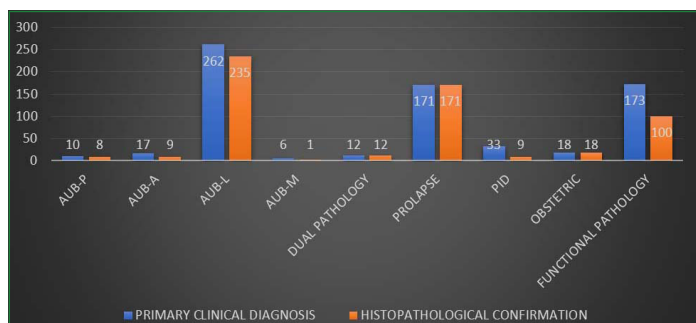
The results were analysed to see the number of cases in which the primary clinical diagnosis was confirmed on histology and a concordance percentage calculated [Table/Fig-8,9].

Of the 529 cases clinically suspected of a structural pathology, the diagnosis was histologically confirmed in 463 cases with 87.52% overall concordance. Of these in 322 cases the agreement was perfect and in 141 additional structural abnormalities apart from primary clinical suspicion, were identified on histology. In the remaining 66 cases where a particular structural pathology was clinically suspected, 34 cases showed a different structural pathology than clinically

suspected and in 32 cases no structural pathology was detected histologically. Good clinicopathological correlation was observed with AUB-P (80%), AUB-L (89.69%), prolapse (100%) and obstetric pathologies (100%). Low concordance between clinical judgement and histopathological diagnosis was seen with AUB-A, AUB-M and PID (52.94%,16.67%, 27.27% respectively) [Table/Fig-9].



**[Table/Fig-7]:** Co-existent premalignant/dysplastic cervical epithelial lesions (Haematoxylin and Eosin stain); a) Koilocytic atypia/Low grade squamous intraepithelial lesion (LSIL) [x100]; b) High grade squamous intraepithelial lesion (HSIL) [x100].



**[Table/Fig-8]:** Correlation of clinical and histopathological diagnosis. \*AUB-P [Abnormal Uterine Bleeding-Polyp]; AUB-A [Abnormal Uterine Bleeding-Adenomyosis]; AUB-L [Abnormal Uterine Bleeding-Leiomyoma]; AUB-M [Abnormal Uterine Bleeding-Hyperplasia/Malignancy]; PID [Pelvic Inflammatory Disease]

Primary clinical diagnosis	Total no. of cases	No. of cases That were histologically confirmed	Concordance Percentage (%)	
<b>1. Structural Pathology</b>	529	463	87.52	
AUB-PALM	Polyp	10	08	80
	Adenomyosis	17	09	52.94
	Leiomyoma	262	235	89.69
	Endometrial hyperplasia	06	01	16.67
Dual Structural Pathology (AUB-PALM /in conjunction with prolapse/PID)	12	12	100	
Prolapse	171	171	100	
Pelvic inflammatory disease	33	09	27.27	
Obstetric Pathology	18	18	100	
<b>2. Functional Pathology (AUB-COEIN)</b>	173	100	57.8	
<b>Total</b>	702	563	80.2	

**[Table/Fig-9]:** Concordance between primary clinical diagnosis and histopathology.

Of the 173 cases suspected of a functional aetiology (AUB-COEIN), 100 cases did not reveal any definite structural pathology on histological examination thus indirectly justifying the primary clinical judgement while 73 cases revealed some structural pathology that was previously missed clinically (57.8% concordance). Of these the most common were AUB-A (28/73) AUB-L (20/73), AUB-A, L (8/73).

A final tabulation and comparison of the cases into different categories as per the two modalities [clinical and histopathological] is shown in [Table/Fig-10].

In comparison to the clinical diagnosis, histopathology revealed structural pathologies in a greater number of cases (570 vs 529 out of 702 cases). This was especially due to additional histological detection of adenomyosis (AUB-A), co-existent dual structural pathologies, premalignant cervical lesions which remained clinically elusive. This difference was found to be statistically significant with p-values less than 0.05 as shown in [Table/Fig-10].

Category	Primary clinical diagnosis (N=702)	Final histopathological diagnosis (N=702)	p-value	
<b>Structural pathology</b>	529 (75.36%)	570 (81.2%)	0.0078 (S)	
AUB	P	10 (1.42%)	13 (1.85%)	0.6741 (NS)
	A	17 (2.42%)	49 (6.98%)	<0.0001 (HS)
	L	262(37.32%)	201 (28.63%)	0.001 (S)
	M	06 (0.85%)	02 (0.28%)	0.2875 (NS)
	Dual structural pathologies (P, A, A, L; P, A, L; P, L; L, M)	10 (1.42%)	80 (11.4%)	<0.0001 (HS)
Prolapse	171 (24.36%)	115 (16.38%)	0.0002 (S)	
Prolapse coexistent with other structural pathology of PALM category	01 (0.14%)	57 (8.12%)	<0.0001 (HS)	
Pelvic inflammatory disease	33 (4.7%)	17 (2.42%)	0.0307 (S)	
Pelvic inflammatory Disease coexistent with other structural pathology of PALM category	01 (0.14%)	12 (1.7%)	0.0053 (S)	
Obstetric pathology	18 (2.56%)	18 (2.56%)	1.0000 (NS)	
Premalignant cervical Lesions (LSIL/HSIL)	00 (0%)	06 (0.85%)	0.0309 (S)	
<b>Functional pathology</b> (No definite structural abnormality)	173 (24.64%)	132 (18.8%)	0.0078 (S)	

**[Table/Fig-10]:** Classification and comparison of cases as per clinical and final histopathological diagnosis.

\*HS: Highly significant; S: Significant; NS: not significant; LSIL: Low grade squamous intraepithelial lesion; HSIL: High grade squamous intraepithelial lesion

The degree of agreement between clinical and histopathological diagnosis with respect to various structural pathologies using Cohen kappa statistical value ( $\kappa$  value) and its interpretation is shown in [Table/Fig-11].

Category of Structural Pathology	$\kappa$ value	Degree of association
AUB-P	0.51	Moderate
AUB-A	0.11	None to slight
AUB-L	0.64	Substantial
AUB-M	0.24	Fair
Dual pathologies (AUB P, A; A, L; P, A, L; P, L; L, M / in conjunction with Prolapse/PID)	0.03	None to slight
Prolapse	1.00	Perfect
PID	0.25	Fair
Obstetric pathology	1.00	Perfect
All structural pathologies	0.27	Fair

**[Table/Fig-11]:** Agreement between clinical and histopathological diagnosis in different structural pathologies. \*Cohen suggested the Kappa result be interpreted as follows: values  $\leq 0$  as indicating no agreement and 0.01-0.20 as none to slight, 0.21-0.40 as fair, 0.41-0.60 as moderate, 0.61-0.80 as substantial, and 0.81-1.00 as almost perfect agreement.

As can be seen, the agreement was almost perfect in cases of prolapse and obstetric pathologies and substantial to moderate with the

diagnosis of AUB-L, AUB-P. However, with AUB-A and dual pathologies the agreement was 'none to slight', since these diagnoses were more often than not missed clinically and detected only on histopathology. With AUB-M and PID, it was fair with cases being suspected clinically but not finding an equivalent histopathological correlation and vice-versa. The overall agreement between clinical and histopathological judgement for structural pathologies was found to be fair ( $\kappa=0.27$ ).

[Table/Fig-12] shows the age-wise distribution of the types of oophorectomies. Total 88.3% (356/403) of the patients who underwent simultaneous oophorectomy (unilateral/bilateral) were under the age of 50 years and a significant proportion of 39.7% (160/403) were under the age of 40 years. However, only 11.41% (46/403) of all the oophorectomies showed some definite structural pathology (endometriosis/salpingo-oophoritis/haemato-salpinx/ hydro-salpinx/ simple serous cyst/ovarian stromal hyperplasia). Most ovaries were unremarkable with others showing functional cysts (cystic follicles, corpus luteal cysts) only.

Age group (Yrs)	Total no.	Adnexa pre-served	USO	BSO	No. with positive pathological finding	Percentage of positive pathological finding (%)
$\leq 30$	25	19	05	01	0/6	0
31-40	229	75	43	111	22/154	14.28
41-50	296	100	34	162	20/196	10.2
51-60	96	56	06	34	4/40	10
>60	56	49	-	07	0/7	0
Total	702	299	88	315	46/403	11.41

**[Table/Fig-12]:** Status and details of adnexae in different age groups.

\*USO: Unilateral salpingo-oophorectomy; BSO: Bilateral salpingo-oophorectomy

## DISCUSSION

The present study was a clinicopathological correlation in a total of 702 hysterectomies performed for non oncological indications in a year across various age groups. As expected, and seen in various other studies too, majority of the patients were in the perimenopausal age group of 41-50 years (42%; 296/702) [10,11]. Understandably, the most frequent guiding indication varied as per different age group with obstetric causes in patients 30 years and below, AUB between 31-50 years and prolapse in patients older than 51 years.

The overall concordance between clinical and histological diagnosis with respect to structural pathologies was found to be good at 87.52%. As compared to clinical diagnosis, histopathological examination detected structural abnormalities in more cases (529 vs 570 out of 702 cases) which was statistically significant too. Similar studies analysing clinicopathological correlation found histopathology detecting more structural pathologies than clinically suspected [Table/Fig-13] [12,13]. This was majorly due to additional histological detection of adenomyosis, co-existent dual structural pathologies like missed leiomyomas, polyps and premalignant cervical lesions.

Authors and studies	Clinical diagnosis of AUB-PALM	Histopathological diagnosis of AUB-PALM*
Present study	75.36% (n=529/702)	81.2% (n=570/702)
Mishra D and Sultan S [12]	50.42% (n=119/236)	63.98% (n=151/236)
Singh K et al., [13]	91.16% (n=134/147)	95.24% (n=140/147)

**[Table/Fig-13]:** Comparative clinicopathological correlation of structural lesions [12,13].

\*Histopathological analysis detected more structural pathologies than clinical suspicion

Clinicopathological correlation showed good concordance of 80% and 89.69% with polyps (AUB-P) and leiomyomas (AUB-L) respectively as these structural lesions are quite easily diagnosed with confidence clinically and radiologically. As shown by  $\kappa$  value too, the clinicopathological agreement in these conditions was moderate and substantial respectively. Majority of the polyps that went clinically



undetected were endometrial polyps as cervical polyps were more easily spotted on per speculum examination. Overall histopathology detected more polyps but the difference was not statistically significant. Our findings were similar to other such studies [12,13].

Majority (86.6%) of clinically missed leiomyomas which were detected on histopathology were small [around 1 cm in diameter]. In most cases the clinical impression was AUB due to functional causes and PID in others. It's difficult to ascertain whether these small lesions were responsible for the clinical symptoms or mere incidental findings. However, we do know that fibroids can be symptomatic irrespective of their size and location [14].

Adenomyosis did not show a comparative clinicopathological concordance (only 52.94%) with none to slight clinicopathological agreement ( $\kappa=0.11$ ). Other researchers too have highlighted the difficulty in the clinical diagnosis of adenomyosis [12,13,15]. Histopathology detected significantly more cases of adenomyosis ( $p\text{-value}<0.0001$ ). This could be because adenomyosis has vague presenting complaints and can often go undetected radiologically too. Co-existent leiomyomas can also make detection of adenomyosis difficult by transabdominal sonography which was the usual primary radiological investigation employed [12,16,17]. Increased histological identification of adenomyosis as the sole or additional structural abnormality led to reallocation of diagnosis to categories of AUB-A and dual diagnosis like AUB-P, A; A, L; P, A, L respectively.

Histological detection of co-existent dual structural pathologies was significantly higher as compared to clinical suspicion (21.2% vs 1.7%) with none to slight clinicopathological agreement ( $\kappa=0.03$ ). 33% of prolapsed uterus showed additional structural pathologies of PALM category. Co-existent structural pathologies like adenomyosis, leiomyomas or in some cases both can add to the bulkiness of uterus, aggravating pressure on an already weakened pelvic floor thus further contributing to proclivencia.

The AUB-A,L was histologically the most commonly detected dual pathology followed by AUB-P,L. Detection of additional unsuspected structural pathologies led to reallocation of the AUB-PALM category emphasising the role of histopathology as a complementary diagnostic tool in PALM component of AUB [12,18,19].

More cases of AUB due to endometrial hyperplasia (AUB-M) were suspected clinically with no corresponding histopathological confirmation showing a low concordance of 16.67%. Most of these cases revealed some other structural pathology belonging to AUB-PALM category. Singh K et al found a better clinicopathological concordance [55.6%] in AUB-M [13]. Mishra D and Sultan S found more cases of AUB-M diagnosed histologically than clinically, with the difference being statistically significant [12]. The present study however, did not reveal any significant increase in histological detection of endometrial hyperplasia. This was probably because Singh K et al and Mishra D and Sultan S included cases of endometrial malignancies in their study, while the present study excluded all oncological causes of hysterectomies.

With PID too, the clinicopathological agreement was only fair ( $\kappa=0.25$ ) with clinically suspected cases not finding corresponding histological affirmation and vice-versa. This could be because endometrial hyperplasia and PID are associated with non specific clinical presentations which can overlap with other causes of AUB and there is no single test sensitive or specific enough for definite clinical diagnosis.

Hysterectomy performed for AUB due to suspected functional aetiology (AUB-COEIN) showed a corresponding 57.8% histological concordance. Absence of a definite structural pathology on histology was taken as an agreement to primary clinical diagnosis as AUB-COEIN component does not show any specific histological findings. In the remaining 42% cases clinically suspected of a functional

aetiology, structural lesions like adenomyosis, leiomyomas, or both were detected thus reassigning the cause of AUB from suspected functional cause to structural category.

Conversely, in 32 cases a primary structural pathology was clinically assigned but histopathology was unremarkable, thus reallocating the diagnosis from structural to functional aetiology.

This reiterates the complementary role of the two modalities with histological assessment helping in putting clinical diagnosis in the correct perspective and guiding appropriate management plan thus ultimately benefiting the patient [12].

Clinicopathological findings were perfectly complementary in obstetric cases as clinical judgement in these conditions is unquestionable.

A significant 88% of patients undergoing simultaneous adnexa removal [unilateral/bilateral] were younger than 50 years. However, only a nominal 11.41% showed some definite pathology on histological examination. Age of the patient, route of hysterectomy and concomitant gynaecologic diagnosis are some of the guiding factors that influence the decision of oophorectomy. Whether or not to preserve ovaries at the time of hysterectomy for benign conditions is a topic of debate. Preserving ovaries is associated with future complications of residual ovary syndrome and ovarian cancer risk while removing them especially in premenopausal women may set in early menopause and complications of hormone replacement therapy. Therefore, a final decision should be established on an individual basis, taking into consideration age, individual and family risk factors, the patient's preference and ability to ensure long-term compliance to exogenous hormone replacement therapy [8,20,21,22].

### Limitation(s)

The fact that the diagnosis of the functional causes of abnormal uterine bleeding was essentially based on exclusion of a primary structural pathology was the main limitation of the research. A detailed work up of these cases would have greatly enhanced the understanding of the aetiopathogenesis of abnormal uterine bleeding.

### CONCLUSION(S)

The present study showed a good concordance between primary clinical diagnosis and histopathological findings with an overall fair degree of agreement between the two. Histopathology is a vital tool to verify the appropriateness of the clinical indication of surgical procedures like hysterectomy which has a profound impact on a woman's overall well-being. Frequent clinicopathological correlation studies can help in improving knowledge and expertise of the healthcare provider, improving future clinical judgements thus, benefitting patients.

### REFERENCES

- [1] Desai S, Shukla A, Nambiar D, Ved R. Patterns of hysterectomy in India: a national and state-level analysis of the Fourth National Family Health Survey (2015-2016). *BJOG*. 2019 Aug;126 Suppl 4(Suppl Suppl 4):72-80. [Doi: 10.1111/1471-0528.15858. PMID: 31309706; PMCID: PMC6772015].
- [2] Ding DC, Tsai IJ, Hsu CY, Wang JH, Lin SZ, Sung FC. Risk of hypertension after hysterectomy: a population-based study. *BJOG*. 2018 Dec;125(13):1717-24. [doi: 10.1111/1471-0528.15389. Epub 2018 Aug 6. PMID: 29953717].
- [3] Yeh JS, Cheng HM, Hsu PF, Sung SH, Liu WL, Fang HL, et al. Hysterectomy in young women associates with higher risk of stroke: a nationwide cohort study. *Int J Cardiol*. 2013 Oct 3;168(3):2616-21. [Doi: 10.1016/j.ijcard.2013.03.042. Epub 2013 Apr 12. PMID: 23587399].
- [4] Ingelsson E, Lundholm C, Johansson AL, Altman D. Hysterectomy and risk of cardiovascular disease: A population-based cohort study. *Eur Heart J*. 2011 Mar;32(6):745-50. [Doi: 10.1093/eurheartj/ehq477. Epub 2010 Dec 24. PMID: 21186237].
- [5] Svejme O, Ahlborg HG, Nilsson JÅ, Karlsson MK. Early menopause and risk of osteoporosis, fracture and mortality: A 34-year prospective observational study in 390 women. *BJOG*. 2012 Jun;119(7):810-6. [Doi: 10.1111/j.1471-0528.2012.03324.x. Epub 2012 Apr 25. PMID: 22531019].

- [6] Rocca WA, Grossardt BR, Shuster LT, Stewart EA. Hysterectomy, oophorectomy, estrogen, and the risk of dementia. *Neurodegener Dis.* 2012;10(1-4):175-8. [Doi: 10.1159/000334764. Epub 2012 Jan 21. PMID: 22269187; PMCID: PMC3702015].
- [7] Fletcher HM, Bennett F, Simms-Stewart D, Reid M, Williams NP, Wharfe GH, et al. Cardiovascular disease risk factors in menopausal Jamaican black women after hysterectomy and bilateral oophorectomy: An observational study. *West Indian Med J.* 2010 Dec;59(6):625-32. [https://www.mona.uwi.edu/fms/wimj/article/1321].
- [8] Piver MS. Prophylactic Oophorectomy: Reducing the U.S. Death Rate from Epithelial Ovarian Cancer. *A Continuing Debate. Oncologist.* 1996;1(5):326-30. [PMID: 10388011].
- [9] Munro MG, Critchley HO, Broder MS, Fraser IS; FIGO Working Group on Menstrual Disorders. FIGO classification system (PALM-COEIN) for causes of abnormal uterine bleeding in nonpregnant women of reproductive age. *Int J Gynaecol Obstet.* 2011 Apr;113(1):3-13. [Doi: 10.1016/j.ijgo.2010.11.011. Epub 2011 Feb 22. PMID: 21345435].
- [10] Tiwana KK, Nibhoria S, Monga T, Phutela R. Histopathological audit of 373 non-oncological hysterectomies in a teaching hospital. *Patholog Res Int.* 2014; 46875:1-5. [http://dx.doi.org/10.1155/2014/468715].
- [11] Sivapragasam V, Rengasamy C, Patil A. An audit of hysterectomies: indications, complications and clinicopathological analysis of hysterectomy specimens in a tertiary care center. *Int J Reprod Contracept Obstet Gynecol.* 2018;7(9):3689-94. [Doi: http://dx.doi.org/10.18203/2320-1770.ijrcog20183778].
- [12] Mishra D, Sultan S. FIGO's PALM-COEIN Classification of Abnormal Uterine Bleeding: A Clinico-histopathological Correlation in Indian Setting. *J Obstet Gynaecol India.* 2017 Apr;67(2):119-25. [Doi: 10.1007/s13224-016-0925-8. Epub 2016 Jul 28. PMID: 28405119; PMCID: PMC5371517].
- [13] Singh K, Agarwal C, Pujani M, Raychaudhuri S, Sharma N, Chauhan V, et al. A Clinicopathological Correlation of International Federation of Gynecology and Obstetrics's PALM-COEIN Classification of Abnormal Uterine Bleeding: Indian Scenario. *J Midlife Health.* 2019 Jul-Sep;10(3):147-52. [Doi: 10.4103/jmh. JMH\_128\_18. PMID: 31579169; PMCID: PMC6767954].
- [14] Sulaiman S, Khaund A, McMillan N, Moss J, Lumsden MA. Uterine fibroids- do size and location determine menstrual blood loss? *Eur J Obstet Gynecol Reprod Biol.* 2004;115(1):85-9. [Doi: 10.1016/j.ejogrb.2003.10.027. PMID: 15223171].
- [15] Shukla M, Fonseca M, Kharat D, Tekale P. A study to correlate histopathological findings in patients with abnormal uterine bleeding. *Int J Reprod Contracept Obstet Gynecol.* 2017;6(2):654-57. [Doi:http://dx.doi.org/10.18203/2320-1770.ijrcog20170401].
- [16] Sakhel K, Abuhamad A. Sonography of adenomyosis. *J Ultrasound Med.* 2012;31(5):805-8. [Doi: 10.7863/jum.2012.31.5.805. PMID: 22535729].
- [17] Bazot M, Daraï E, Rouger J, Detchev R, Cortez A, Uzan S. Limitations of transvaginal sonography for the diagnosis of adenomyosis, with histopathological correlation. *Ultrasound Obstet Gynecol.* 2002 Dec;20(6):605-11. [Doi: 10.1046/j.1469-0705.2002.00852.x. PMID: 12493051].
- [18] Ramachandran T, Sinha P, Subramaniam. Correlation between clinicopathological and ultrasonographical findings in hysterectomy. *J Clin Diagn Res.* 2011;5(4):737-40. [https://www.jcdr.net/articles/pdf/1478/13\_2895.pdf].
- [19] Khan S, Hameed S, Umber A. Histopathological pattern of endometrium on diagnostic D&C in patients with abnormal uterine bleeding. *ANNALS.* 2011;17(2):166-70. [https://doi.org/10.21649/akemu.v17i2.293].
- [20] Dekel A, Efrat Z, Orvieto R, Levy T, Dicker D, Gal R, et al. The residual ovary syndrome: a 20-year experience. *Eur J Obstet Gynecol Reprod Biol.* 1996 Sep;68(1-2):159-64. [Doi: 10.1016/0301-2115(96)00250-3. PMID: 8886700].
- [21] Parker WH, Broder MS, Liu Z, Shoupe D, Farquhar C, Berek JS. Ovarian conservation at the time of hysterectomy for benign disease. *Obstet Gynecol.* 2005 Aug;106(2):219-26. [Doi: 10.1097/01.AOG.0000167394.38215.56. PMID: 16055568].
- [22] Evans EC, Matteson KA, Orejuela FJ, Alperin M, Balk EM, El-Nashar S, et al. Society of Gynecologic Surgeons Systematic Review Group. Salpingo-oophorectomy at the Time of Benign Hysterectomy: A Systematic Review. *Obstet Gynecol.* 2016 Sep;128(3):476-85. [Doi: 10.1097/AOG.0000000000001592. PMID: 27500347; PMCID: PMC5100819].

**PARTICULARS OF CONTRIBUTORS:**

1. Associate Professor, Department of Pathology, J.L.N Medical College, Ajmer, Rajasthan, India.

**NAME, ADDRESS, E-MAIL ID OF THE CORRESPONDING AUTHOR:**

Dr. Kalpana Sharma,  
B 21, Arawali Vihar, Ajmer, Rajasthan, India.  
E-mail: pkss75780507@gmail.com

**PLAGIARISM CHECKING METHODS:** [Jain H et al.]

- Plagiarism X-checker: Jan 24, 2022
- Manual Googling: Mar 26, 2022
- iThenticate Software: Apr 09, 2022 (6%)

**ETYMOLOGY:** Author Origin**AUTHOR DECLARATION:**

- Financial or Other Competing Interests: None
- Was Ethics Committee Approval obtained for this study? Yes
- Was informed consent obtained from the subjects involved in the study? No
- For any images presented appropriate consent has been obtained from the subjects. No

Date of Submission: **Jan 09, 2022**Date of Peer Review: **Feb 22, 2022**Date of Acceptance: **Mar 28, 2022**Date of Publishing: **Jul 01, 2022**